CHAPTER 10

Gallstone: a lead factor for gallstone cancer

Ajit Kumar Kushwaha[1], Sumedha Gargy[1] and Soni Prasad[2]
[1]Department of Surgical Oncology, RIMS, Ranchi, Jharkhand, India
[2]Atal Clinic, Doranda, Ranchi, Jharkhand, India

Introduction

Gallbladder cancer (GBC), is the most common and aggressive biliary tract malignancy. The person suffering from GBC has a very low survival rate. The median overall survival is estimated to be 10.3 months from the time of diagnosis. Globally, India, Chile, and Mexico were considered major prevalent region for GBC (Ferlay et al., 2015). The International Agency for Research on Cancer (IARC) reported around 220,000 new cases of GBC every year globally with accounts for 1.7% of all cancer deaths, and the incidence is expected to rise globally every year (Bray et al., 2018).

An epidemiological study in India states its preponderance in north, north-east central, and eastern India. In north India, the reported incidence is 10–22/100,000 population (Dutta et al., 2019). This may be due to the early onset of gallstones in this population (Sampliner et al., 1970). yielding a prolonged exposure period. The same could be a possible cause of its preponderance to females. Females are affected more frequently than males (0.3–8.9 per 100,000 population vs 0.1–3.7 per 100,000 population) (Nandakumar, 1990).

GBC incidence increases with age, the greatest being at 65 years and older. However, isolated reports of GBC diagnosed in children have also been found (De Aretxabala et al., 1997). One percent of patients undergoing cholecystectomy for cholelithiasis have an incidental GB carcinoma (Panebianco et al., 2018; Wanebo & Vezeridis, 1993).

As per the data from The Global Cancer Observatory (GLOBOCAN), the incidence of GBC in 2020 is alarming (Fig. 10.1A) and is predicted to increase exponentially by 2040 (Fig. 10.1B). The developed countries laparoscopic cholecystectomies have stabilized the rising number of GBC (Nervi et al., 1988). This chapter has tried to present an overview on different aspects of GBC.

Gallstone Formation, Diagnosis, Treatment, and Prevention
DOI: https://doi.org/10.1016/B978-0-443-16098-1.00009-6
© 2024 Elsevier Inc. All rights are reserved, including those for text and data mining, AI training, and similar technologies.

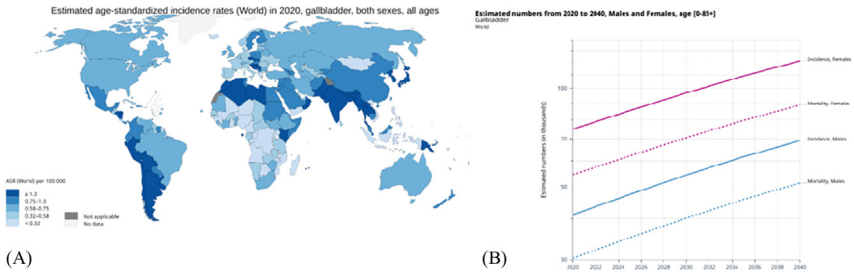

Figure 10.1 (A) Analysis of GBC in 2020 as per Incidence of Global Cancer Observatory (GLOBOCAN); (B) Predicted exponential increase in the rate of GBC by 2040. *http://gco.iarc.fr/today*.

Risk factors

Chronic gallbladder cancer due to cholelithiasis is the most common risk factor for gallbladder cancer and the risk increases with the stone size. Other risk factors are porcelain gallbladder, anomalous pancreaticobiliary duct junction, chronic typhoid infection, primary sclerosing cholangitis, adenomyomatosis, gallbladder polyps (> 1 cm), and inflammatory bowel disease.

Evidence suggests that patients with cholelithiasis have an 8.3 × higher risk than the general population (Miller & Jarnagin, 2008). Larger stones carry a greater risk, with stones >3 cm having 9.2–10.1 times increased risk than stones <1 cm (Lai & Lau, 2008). Scientific data suggest a direct relation between the GBC and Gallstone cases (Fig. 10.2).

Signs and symptoms

GBC does not have any specific symptoms or effective screening measures. Patients are often asymptomatic with right upper abdominal pain mimicking biliary colic in the early stages. This is the major factor for fatality. Associated recent weight loss, especially in patients older than 65 years should raise a high index of suspicion for GBC. The development of obstructive jaundice following disease progression and biliary outflow obstruction indicated the advancement of cancer. Jaundice is a poor prognostic sign with 85% of patients having unresectable tumors. Physical examination may demonstrate a lump, hepatomegaly, and jaundice (Kai, 2014).

Pathogenesis

GBC mostly arises in the fundus (60%) followed by the body (30%) or neck (10%) region of the gallstone (House et al., 2003). Cancer develops

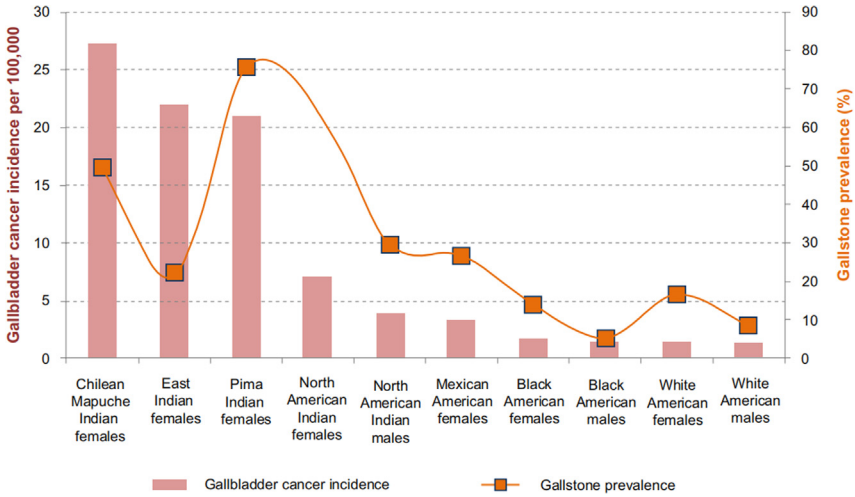

Figure 10.2 Prevalence of gallstone cancer in gallstone patients. *Clinical Epidemiology, 2014, 6, 99–109. Originally published by and used with permission from Dove Medical Press Ltd.*

over a span of 5–15 years, with tissue alterations including metaplasia, dysplasia, carcinoma *in situ*, and invasive cancer (Hundal & Shaffer, 2014).

The anatomical position and structure of the gallbladder predisposes it to early invasion of adjacent structures and lymph node involvement, thus rendering early detection imperative as a loss in chance of surgical resection carries a very poor prognosis. Having a thin mucosal wall, a narrow lamina propria, and only a single muscle layer, once the gallbladder is penetrated, the tumor gets access to major lymphatic and vascular channels causing early lymphatic and hematogenous spread. In addition, the attachment of the gallbladder to the liver has no serosa thus causing direct infiltration of GBC to the liver to be the most common form of direct local spread (Andrén-Sandberg & Deng, 2014; Yoshimitsu et al., 2012). In this regard, a study carried out by Memorial Sloan-Kettering Cancer Center (MSKCC) demonstrated that 36.6% of GBC patients are at the American Joint Committee on Cancer (AJCC) stage IV when diagnosed (Lammert et al., 2016). Infundibulum or cystic duct tumors can obstruct the common bile duct and involve the portal vein.

At initial presentation, only 10% of patients are candidates for surgery with curative intent (Lowenfels et al., 1985). Even the patients suitable for resection have high mortality rates due to the anatomical complexity of the portobiliary hepatic system, the morbidity/mortality associated with

liver resection, and the risks of tumoural spread following tumor manipulation (Ramos-Font et al., 2014) (Fig. 10.3).

Hence, in order to improve survival from this lethal cancer, early diagnosis and intervention along with close follow-up of high-risk individuals is paramount. However, for GBC, there is a paucity of approved preventive and therapeutic measures. One of the most important and strongly correlated risk factors for GBC is gallstones.

Gallstones are commonly found benign clinical conditions of the gallbladder with worldwide prevalence of 10%–20% (Lammert et al., 2016). A large-scale case-control study by Hsing et al. demonstrated that 83.7% of patients with GBC have a history of gallstones (Hsing et al., 2007). The risk of GBC was increased in a prospective cohort study of patients with gallstones, although the incidence (9 per 10,000 per person-years) and the absolute number of cases of GBC (5 of 2583 people) was low (Maringhini et al., 1987), and 0.5%–1.5% of patients undergoing simple cholecystectomy for presumed cholelithiasis are discovered incidentally to have GBC (Lai & Lau, 2008).

Patients with gallstones and no family history had a 21-fold higher risk of GBC than healthy controls, and those with gallstones and a family history had a 57-fold higher risk. However, only 0.5%–3% of patients with gallstones will develop GBC. Cariati et al. conducted a multicenter study

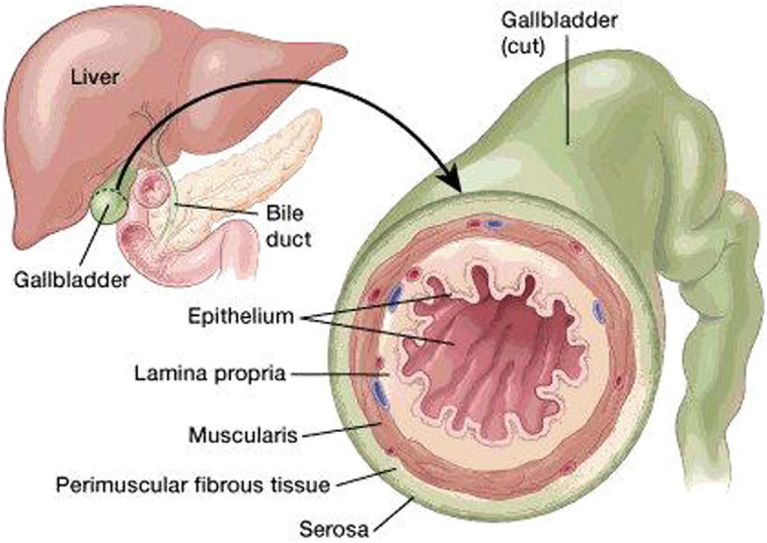

Figure 10.3 Anatomy of gallbladder. *Adapted from American Cancer Society.*

that included 75 patients with GBC and found that 96% of patients had gallstones (Pitt et al., 2014).

A link between the size of gallbladder stones and GBC has also been demonstrated especially with gallstones larger than 3 cm in diameter, the hypothesis being the size indicates chronic inflammation and duration of disease since gallstones are slow-growing. The rate of growth of gallstones has been estimated to be 2 mm per year, suggesting that it would take at least 15 years to reach a size of 3 cm (Lowenfels et al., 1985). This is an important consideration because a long duration of gallstones may be necessary to induce chronic trauma to the mucosa, which initiates the sequence of pathologic changes resulting in cancer development (Shaffer, 2008). Adenocarcinomas progress from metaplasia–dysplasia to carcinoma *in situ* to cancer. The association between the presence of gallstones and GBC is supported by Level II evidence (multiple-cohort studies). In support of this association, an inverse correlation exists between cholecystectomy for cholelithiasis and gallbladder cancer rates (Jørgensen & Jensen, 1990).

While several reports suggest the increased risk of GBC due to gallstones but few reports emphasize on the nature, density, and number of stones affecting prognosis (Khan et al., 1999; Roa et al., 2006). Gallstones can be cholesterol, mixed, or pigmented stones. In Western countries, cholesterol stones account for approximately 75% of GB stones (Interventional, 2016). The findings supporting the role of gallstones in GBC have a strong biological plausibility. Many genetic variants recognized to proxy the presence of gallstones have an association with cholesterol metabolism (Ferkingstad et al., 2018). Cholesterol metabolism has been shown to be a fundamental factor in gallstone formation. Additionally, certain variants (rs56398830 and rs55971546) located proximal to the bile acid transporter, the SLC10A2 gene have a main function to reabsorb bile salts from the terminal ileum into ileocytes, following which they are transported back to the liver through the enterohepatic circulation. As some of the identified variants lead to gallstone modifiable pathways (cholesterol levels and bile salts) relating to genetic liability to gallstones, strategies intervening on these pathways have the potential to reduce gallbladder cancer risk. Hence, studies have demonstrated a reduction in gallstones and biliary tract cancer among long-term statin users (Bodmer et al., 2009; Erichsen et al., 2011; Liu et al., 2019). The presence of bacteria in the bile and gallstones in the gallbladder, and the synergistic

consequence of GBC is a relatively new concept of considerable interest (Sharma et al., 2007).

Staging

According to the American Joint Committee on Cancer (AJCC) staging system, gallbladder cancer is classified into four stages based on tumor depth of invasion, involvement of surrounding organs, and lymph nodes (Table 10.1).

Diagnostic imaging

The most frequent initial diagnostic modality in suspected gallbladder disease is ultrasonography. GBC may have three appearances: (1) mass

Table 10.1 TNM staging of GBC 8th ed., 2017.

Denotation	Classification
Primary tumor	
TX	Primary tumor cannot be assessed
T0	No evidence of primary tumor
T1s	*In situ* carcinoma
T1a	Invades lamina propria
T1b	Invades muscular layer
T2a	Tumor invades the perimuscular connective tissue on the peritoneal side, without involvement of the serosa (visceral peritoneum)
T2b	Tumor invades the perimuscular connective tissue on the hepatic side, with no extension into the liver
T3	Tumor perforates the serosa and or directly invades the liver and or one other adjacent organ or structure, such as the stomach, duodenum, colon, pancreas, omentum, or extrahepatic bile ducts.
T4	Tumor invades the main portal vein or hepatic artery or invades two or more extrahepatic organs or structure
Involvement of regional lymph nodes	
NX	Regional nodes cannot be assessed
N0	Absence of regional lymph node metastasis
N1	Metastasis to one to three regional lymph nodes
N2	Metastasis to four or more regional nodes
Distant metastasis (M)	
M0	No distant metastasis
M1	Distant metastasis

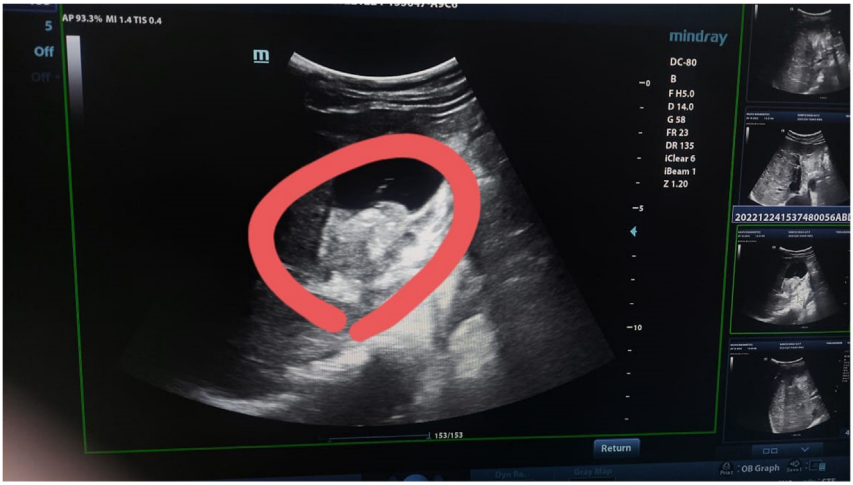

Figure 10.4 USS appearance of asymmetric gallbladder thickening in body and neck region.

replacing or invading the gallbladder, (2) intraluminal growth, and (3) asymmetrical wall thickening (Fig. 10.4).

The detectability of gallstones on CT is affected by their chemical composition. The amount of calcium metabolites in stones indicates their CT scan visibility. Pigment stones generally have better CT visibility as compared to pure cholesterol stones (Interventional, 2016; John et al., 2020; Lee et al., 2006). Contrast material-enhanced CT in GBC cases may demonstrate a hypoattenuating or isoattenuating mass in the gallbladder fossa. Areas of enhancement reflect viable tumors. The most diagnostically challenging subtype is the thickened gallbladder as it mimics chronic inflammation (Fig. 10.5). MRI, MRA, and MRCP have been shown to be superior to CT scans in pre-operative planning.

Management

Gallbladder cancer may present as an incidental finding during surgery or pathological examination. Alternatively, a mass can be found preoperatively on workup of abdominal pain or jaundice. In cases of incidental findings during surgery, management would depend upon the availability of expertise. In cases where expertise is not available, relevant findings should be documented and patient referred to the appropriate center whereas upon the availability of expertise when tumor is deemed

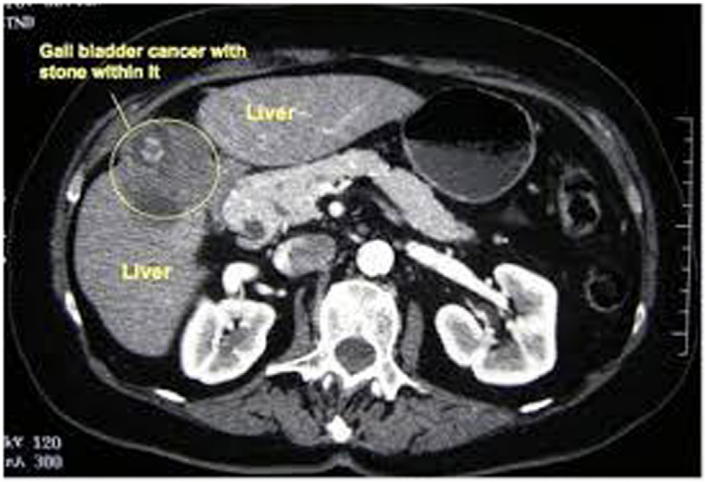

Figure 10.5 CT scan showing asymmetrical wall thickening of gallbladder.

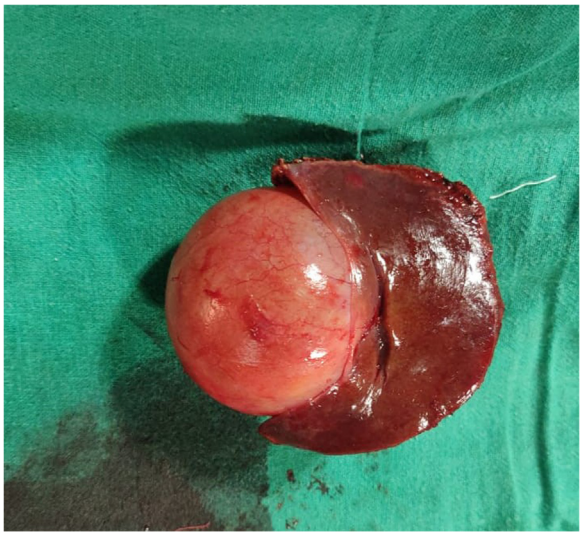

Figure 10.6 Radical cholecystectomy specimen.

resectable, definitive surgery should be carried out. When the diagnosis is uncertain, a frozen section can be used to confirm malignancy. In cases of non-resectable, locally advanced tumors, biopsy can be considered followed by chemotherapy. In cases of incidental pathological finding,

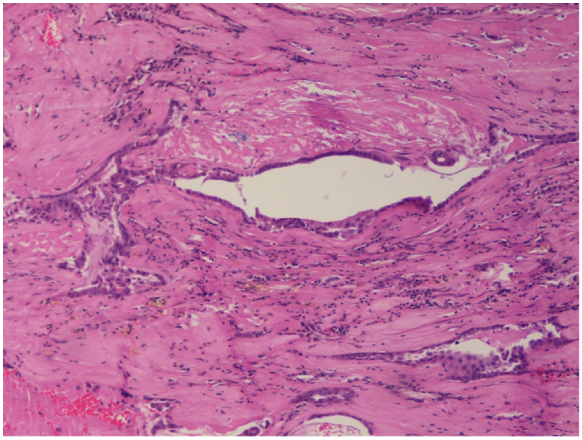

Figure 10.7 The H&E section studied shows a tumor arranged in complex glandular patterns and nests. Tumor cells display moderate pleomorphism, having vesicular nuclei, prominent nucleoli, and moderate amount of cytoplasm.

surgery to obtain clear margins and lymphadenectomy is advised (Figs. 10.6 and 10.7).

Conclusion

Primary carcinoma of the gallbladder is a highly aggressive malignancy that is found at a late stage in the majority of affected patients. Early-stage gallbladder carcinoma is most commonly an incidental finding in patients having undergone cholecystectomy for cholelithiasis. Eradication of gallstones remains the ideal modality for the prevention of GBC given their well-described association with carcinogenesis and the fact that they are easily detected by ultrasound examination with a lead time of 15–20 years (Dutta et al., 2019). However, in this context, the role of prophylactic cholecystectomy in asymptomatic patients remains poorly defined.

Studies on the relationship between gallstones and GBC will lead the way in establishing preventive cholecystectomy as a measure of preventing GBC, especially in high-risk cases (e.g., size > 3 cm, disease duration > 15 years).

Clinicians are urged to operate on patients with multiple small calculi and solitary long-standing large calculus on a priority basis with histopathology in each case, especially with GB wall thickening.

Acknowledgment

The authors are thankful to the patients they treated, and the Dove Medical Press to permit the use of Fig. 10.2 in this chapter.

Conflict of interest

None

References

Andrén-Sandberg, A., & Deng, Y. (2014). Aspects on gallbladder cancer in 2014. *Current Opinion in Gastroenterology*, *30*(3), 326–331. Available from https://doi.org/10.1097/MOG.0000000000000068.

Bodmer, M., Brauchli, Y. B., Krähenbühl, S., Jick, S. S., & Meier, C. R. (2009). Statin use and risk of gallstone disease followed by cholecystectomy. *JAMA: The Journal of the American Medical Association*, *302*(18), 2001–2007. Available from https://doi.org/10.1001/jama.2009.1601.

Bray, F., Ferlay, J., Soerjomataram, I., Siegel, R. L., Torre, L. A., & Jemal, A. (2018). Global cancer statistics 2018: GLOBOCAN estimates of incidence and mortality worldwide for 36 cancers in 185 countries. *CA Cancer Journal for Clinicians*, *68*(6), 394–424. Available from https://doi.org/10.3322/caac.21492.

De Aretxabala, X. A., Roa, I. S., Burgos, L. A., Araya, J. C., Villaseca, M. A., & Silva, J. A. (1997). Curative resection in potentially resectable tumours of the gallbladder. *European Journal of Surgery*, *163*(6), 419–426.

Dutta, U., Bush, N., Kalsi, D., Popli, P., & Kapoor, V. K. (2019). Epidemiology of gallbladder cancer in India. *Chinese Clinical Oncology*, *8*(4). Available from https://doi.org/10.21037/cco.2019.08.03.

Erichsen, R., Frøslev, T., Lash, T. L., Pedersen, L., & Sørensen, H. T. (2011). Long-term statin use and the risk of gallstone disease: A population-based case-control study. *American Journal of Epidemiology*, *173*(2), 162–170. Available from https://doi.org/10.1093/aje/kwq361.

Ferkingstad, E., Oddsson, A., Gretarsdottir, S., Benonisdottir, S., Thorleifsson, G., Deaton, A. M., Jonsson, S., Stefansson, O. A., Norddahl, G. L., Zink, F., Arnadottir, G. A., Gunnarsson, B., Halldorsson, G. H., Helgadottir, A., Jensson, B. O., Kristjansson, R. P., Sveinbjornsson, G., Sverrisson, D. A., Masson, G., . . . Stefansson, K. (2018). Genome-wide association meta-analysis yields 20 loci associated with gallstone disease. *Nature Communications*, *9*(1). Available from https://doi.org/10.1038/s41467-018-07460-y.

Ferlay, J., Soerjomataram, I., Dikshit, R., Eser, S., Mathers, C., Rebelo, M., Parkin, D. M., Forman, D., & Bray, F. (2015). Cancer incidence and mortality worldwide: Sources, methods and major patterns in GLOBOCAN 2012. *International Journal of Cancer*, *136*(5), E359–E386. Available from https://doi.org/10.1002/ijc.29210.

House, M. G., Wistuba, I. I., Argani, P., Guo, M. Z., Schulick, R. D., Hruban, R. H., Herman, J. G., & Maitra, A. (2003). Progression of gene hypermethylation in gallstone disease leading to gallbladder cancer. *Annals of Surgical Oncology*, *10*(8), 882–889. Available from https://doi.org/10.1245/ASO.2003.02.014.

Hsing, A. W., Bai, Y., Andreotti, G., Rashid, A., Deng, J., Chen, J., Goldstein, A. M., Han, T. Q., Shen, M. C., Fraumeni, J. F., & Gao, Y. T. (2007). Family history of gallstones and the risk of biliary tract cancer and gallstones: A population-based study

in Shanghai, China. *International Journal of Cancer*, *121*(4), 832–838. Available from https://doi.org/10.1002/ijc.22756.

Hundal, R., & Shaffer, E. A. (2014). Gallbladder cancer: Epidemiology and outcome. *Clinical Epidemiology*, *6*(1), 99–109. Available from https://doi.org/10.2147/CLEP.S37357.

Interventional, N. V. (2016). Part VI: Non-vascular interventional procedures: Hepatobiliary-gallbladder. In B. Taslakian, A. Al-Kutoubi, & J. J. Hoballah (Eds.), *Procedural dictations in image-guided intervention: Non-vascular, vascular and neuro interventions*. Springer.

John, S., Moyana, T., Shabana, W., Walsh, C., & McInnes, M. D. F. (2020). Gallbladder cancer: Imaging appearance and pitfalls in diagnosis. *Canadian Association of Radiologists Journal*, *71*(4), 448–458. Available from https://doi.org/10.1177/0846537120923273.

Jørgensen, T., & Jensen, K. H. (1990). Polyps in the gallbladder: A prevalence study. *Scandinavian Journal of Gastroenterology*, *25*(3), 281–286.

Kai, K. (2014). Gallbladder cancer: Clinical and pathological approach. *World Journal of Clinical Cases*, *2*(10), 515. Available from https://doi.org/10.12998/wjcc.v2.i10.515.

Khan, Z. R., Neugut, A. I., Ahsan, H., & Chabot, J. A. (1999). Risk factors for biliary tract cancers. *American Journal of Gastroenterology*, *94*(1), 149–152. Available from https://doi.org/10.1111/j.1572-0241.1999.00786.x.

Lai, C. H. E., & Lau, W. Y. (2008). Gallbladder cancer—A comprehensive review. *The Surgeon*, *6*(2), 101–110. Available from https://doi.org/10.1016/s1479-666x(08)80073-x.

Lammert, F., Gurusamy, K., Ko, C. W., Miquel, J. F., Méndez-Sánchez, N., Portincasa., Erpecum, K. J., Laarhoven, V., & Wang, D. Q. H. (2016). Gallstones. *Nature Reviews Disease Primers*, *2*, 1–17.

Lee, J. K., Kim, T. K., Byun, J. H., Kim, A. Y., Ha, H. K., Kim, P. N., & Lee, M. G. (2006). Diagnosis of intrahepatic and common duct stones: Combined unenhanced and contrast-enhanced helical CT in 1090 patients. *Abdominal Imaging*, *31*(4), 425–432. Available from https://doi.org/10.1007/s00261-006-9076-1.

Liu, Z., Alsaggaf, R., Mcglynn, K. A., Anderson, L. A., Tsai, H. T., Zhu, B., Zhu, Y., Mbulaiteye, S. M., Gadalla, S. M., & Koshiol, J. (2019). Statin use and reduced risk of biliary tract cancers in the UK Clinical Practice Research Datalink. *Gut*, *68*(8), 1458–1464. Available from https://doi.org/10.1136/gutjnl-2018-317504.

Lowenfels, A. B., Lindstrom, C. G., Conway, M. J., & Hastings, P. R. (1985). Gallstones and risk of gallbladder cancer. *Journal of the National Cancer Institute*, *75*(1), 77–80.

Maringhini, A., Moreau, J. A., Melton, L. J., Hench, V. S., Zinsmeister, A. R., & DiMagno, E. P. (1987). Gallstones, gallbladder cancer, and other gastrointestinal malignancies. An epidemiologic study in Rochester, Minnesota. *Annals of Internal Medicine*, *107*(1), 30–35. Available from https://doi.org/10.7326/0003-4819-107-1-30.

Miller, G., & Jarnagin, W. R. (2008). Gallbladder carcinoma. *European Journal of Surgical Oncology (EJSO)*, *34*(3), 306–312. Available from https://doi.org/10.1016/j.ejso.2007.07.206.

Nandakumar, A. (1990). *National cancer registry programme*. Indian Council of Medical Research. Consolidated report of the population based cancer registries.

Nervi, F., Duarte, I., Gómez, G., Rodríguez, G., Pino, G. D., Ferrerio, O., Covarrubias, C., Valdivieso, V., Torres, M. I., & Urzúa, A. (1988). Frequency of gallbladder cancer in chile, a high-risk area. *International Journal of Cancer*, *41*(5), 657–660. Available from https://doi.org/10.1002/ijc.2910410503.

Panebianco, A., Laforgia, R., Volpi, A., Mancarella, R., Carbotta, G., Punzo, C., Lozito, C., Tucci, R., Minafra, M., Delvecchio, A., Fedele, S., Ialongo, P., Paterno, A., & Palasciano, N. (2018). Predictive factors for incidental gallbladder cancer (IGBC) in patients undergoing cholecystectomy for presumed benign disease. A single-center

experience. *Annali Italiani di Chirurgia*, *89*(2), 118–127. Available from http://www.annitalchir.com.

Pitt, S. C., Jin, L. X., Hall, B. L., Strasberg, S. M., & Pitt, H. A. (2014). Incidental gallbladder cancer at cholecystectomy: When should the surgeon be suspicious? *Annals of Surgery*, *260*(1), 128–133. Available from https://doi.org/10.1097/SLA.0000000000000485.

Ramos-Font, C., Gómez-Rio, M., Rodríguez-Fernández, A., Jiménez-Heffernan, A., Sánchez, R. S., & Llamas-Elvira, J. M. (2014). Ability of FDG-PET/CT in the detection of gallbladder cancer. *Journal of Surgical Oncology*, *109*(3), 218–224. Available from https://doi.org/10.1002/jso.23476.

Roa, I., Ibacache, G., Roa, J., Araya, J., De Aretxabala, X., & Muñoz, S. (2006). Gallstones and gallbladder cancer-volume and weight of gallstones are associated with gallbladder cancer: A case-control study. *Journal of Surgical Oncology*, *93*(8), 624–628, John Wiley and Sons Inc. Available from https://doi.org/10.1002/jso.20528.

Sampliner, R. E., Bennett, P. H., Comess, L. J., Rose, F. A., & Burch, T. A. (1970). Gallbladder disease in Pima Indians: Demonstration of high prevalence and early onset by cholecystography. *New England Journal of Medicine*, *283*(25), 1358–1364. Available from https://doi.org/10.1056/NEJM197012172832502.

Shaffer, E. A. (2008). Gallbladder cancer: The basics. *Gastroenterology and Hepatology*, *4*(10), 737–741.

Sharma, V., Chauhan, V. S., Nath, G., Kumar, A., & Shukla, V. K. (2007). Role of bile bacteria in gallbladder carcinoma. *Hepato-Gastroenterology*, *54*(78), 1622–1625.

Wanebo, H. J., & Vezeridis, M. P. (1993). Carcinoma of the gallbladder. *Journal of Surgical Oncology*, *53*(3 S), 134–139. Available from https://doi.org/10.1002/jso.2930530536.

Yoshimitsu, K., Nishihara, Y., Okamoto, D., Ushijima, Y., Nishie, A., Yamaguchi, K., Taketomi, A., & Honda, H. (2012). Magnetic resonance differentiation between T2 and T1 gallbladder carcinoma: Significance of subserosal enhancement on the delayed phase dynamic study. *Magnetic Resonance Imaging*, *30*(6), 854–859. Available from https://doi.org/10.1016/j.mri.2012.02.016.